



PATIENT

Obi Won Calvo

SPECIES

Feline

BREED

DSH

SEX

Male Neutered

AGE

4 years

WEIGHT

15.44lbs

INTERPRETED BY

Maggie Machen
Lamy, DVM
DACVIM (Cardiology)

IMAGING PERFORMED BY

Pamela Harrigan,
RDCS

HOSPITAL NAME

Mass Veterinary Services

REFERRING VET

Dr. Masloski

INVOICE

29908

DATE

3/29/23

PRESENTING CLINICAL SIGNS

History: Obi Won is referred to evaluate a heart murmur. He is on a weight loss regimen. He is eating well and remains active with no C/S/V/D/PU/PD. On exam: NSR, grade II/VI parasternal murmur, PSS, lung fields clear, compressible thorax, mm pink, moist, CRT<2. BP: 120-130mmHg. Currently, no medications. *Sedated with propofol for study.

ECHOCARDIOGRAM FINDINGS

2D, m-mode, color flow and Doppler imaging is available.

Left ventricle: The LV diameter is normal with adequate myocardial function. The LV wall thicknesses are normal. The papillary muscles are normal. The endocardium appears mildly hyperechoic.

Left atrium: The left atrium is normal in dimension. No obvious spontaneous contrast or thrombi seen.

Mitral valve: The mitral valve is normal in structure and mobility. No obvious systolic anterior motion is seen. No MR.

Aortic valve/Aorta: The aortic valve is normal in morphology and mobility. Normal aortic outflow velocity; laminar flow. No aortic insufficiency.

Right ventricle: Normal right ventricular diameter and morphology indicating no overt evidence of pulmonary arterial hypertension.

Right atrium: The right atrium is normal in dimension.

Tricuspid valve: The tricuspid valve appears normal with trace tricuspid regurgitation.

Pulmonic valve/Pulmonary artery: The pulmonic valve is normal in morphology and mobility. Trace pulmonic insufficiency. Normal RVOT velocity; laminar flow.

Pericardium/other: No pericardial or pleural effusion noted. No obvious cardiac masses.

Heart rhythm: ECG reveals a sinus rhythm with an average HR of 160bpm.

2-Dimensional Measurements

Ao diam (cm)	0.9
LA diam (cm)	1.2
LA:Ao (Swe)	1.3
IVS thickness (cm)	0.42
LVID diastole (cm)	1.57
PW thickness (cm)	0.50
LVID systole (cm)	0.9
FS (%)	43

Doppler Measurements

PV Vmax (m/s)	0.6
AoV Vmax (m/s)	0.76
MR Vmax (m/s)	NA
TR Vmax (m/s)	NA
TR PG (mmHg)	NA

INTERPRETATION OF THE FINDINGS

Overtly normal cardiac structure and function. The LV wall thickness is normal and there is no evidence of elevated left atrial pressure. No cause for the murmur is identified in this study (likely due to sedation), making it likely physiologic in origin (i.e., secondary to tachycardia, volume changes, etc.).

Prognosis is open.

RECOMMENDATIONS

- Given these findings, no medications are indicated.
- No cardiac contraindication for general anesthesia.
- Monitor for any clinical evidence of cardiac compromise, including respiratory changes and/or signs of a blood clot event (paralysis, neurologic changes, etc.).



PATIENT

Obi Won Calvo

PLAN

- Recommend recheck echocardiogram in 1 year to reassess murmur origin and screen for development of disease the pre-existing murmur may mask.

SPECIES

Feline

BREED

DSH

SEX

Male Neutered

AGE

4 years

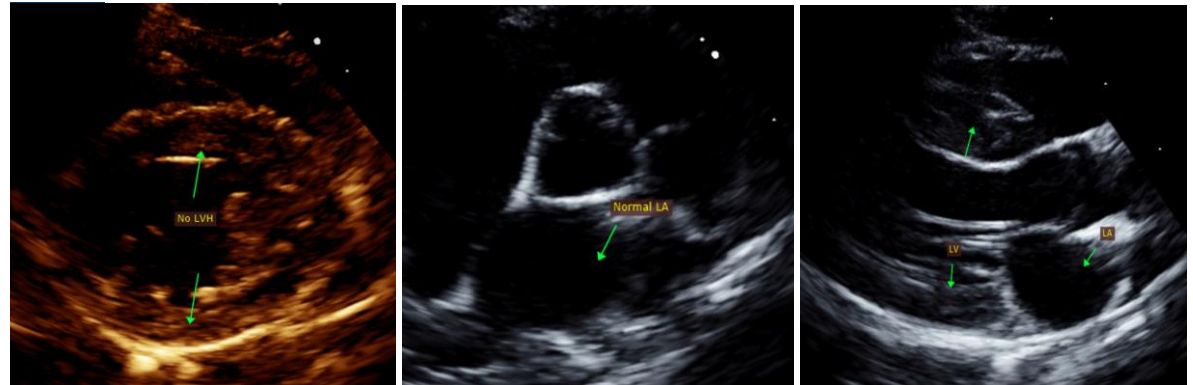
WEIGHT

15.44lbs

INTERPRETED BY

Maggie Machen Lamy, DVM
DACVIM (Cardiology)

IMAGES



The information and recommendations provided are based on the images presented by the referring veterinarian. No evaluation can be communicated regarding pathology that was not visible in the image/video clips provided.

Thank you for this referral. This report was generated using transcription software, and minor dictation errors may be present. If the clinical or image interpretation does not parallel your findings or if I can be of any further assistance, please contact me.

Maggie Machen Lamy, DVM
Diplomate of the American College of Veterinary Internal Medicine (Cardiology)
info@sonopath.com

Echocardiogram performed by: Pamela Harrigan, RDCS
Pet Animal Ultrasound Service (4paus.com)

IMAGING PERFORMED BY

Pamela Harrigan, RDCS

HOSPITAL NAME

Mass Veterinary Services

REFERRING VET

Dr. Masloski

INVOICE

29908

DATE

3/29/23